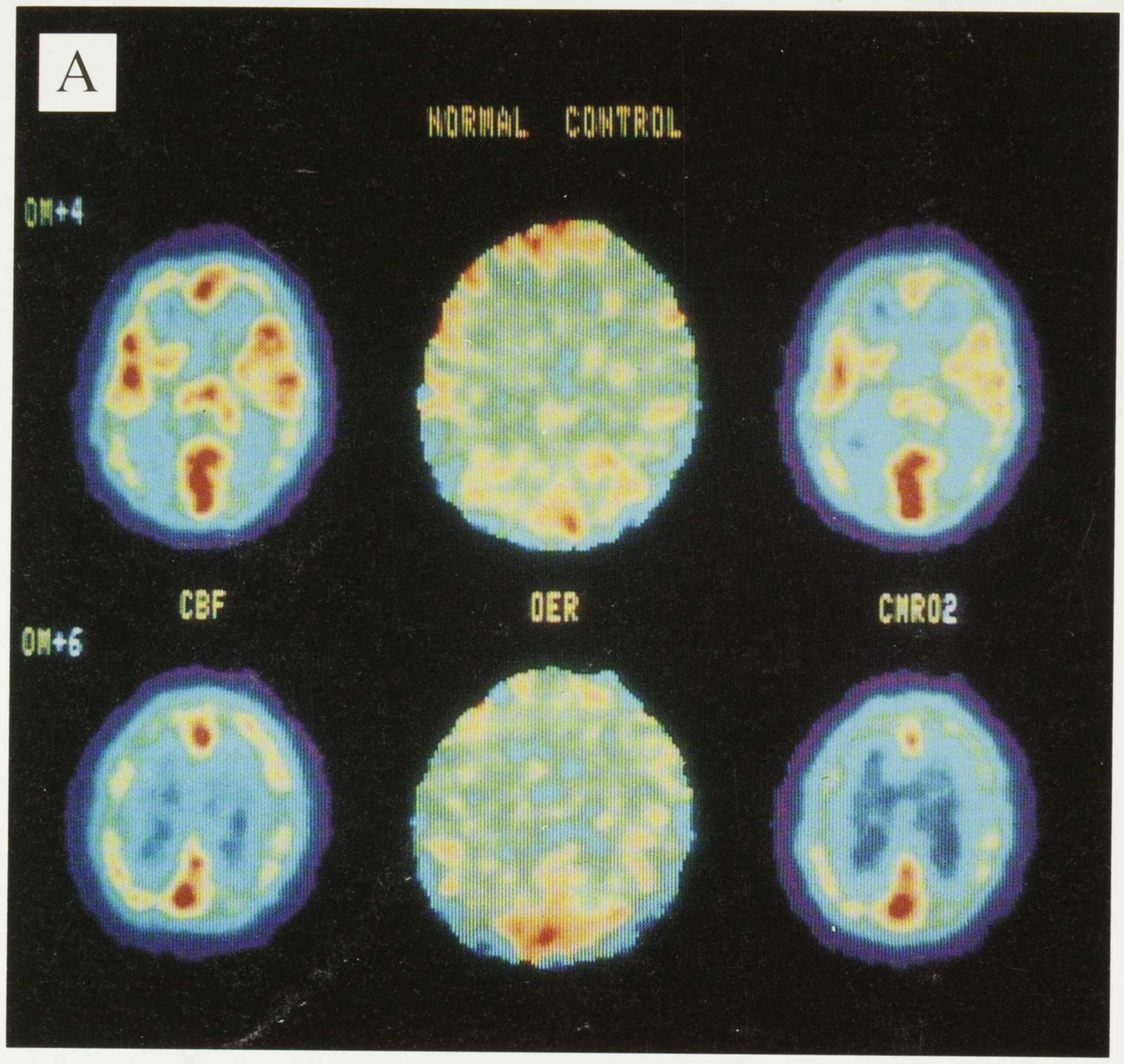

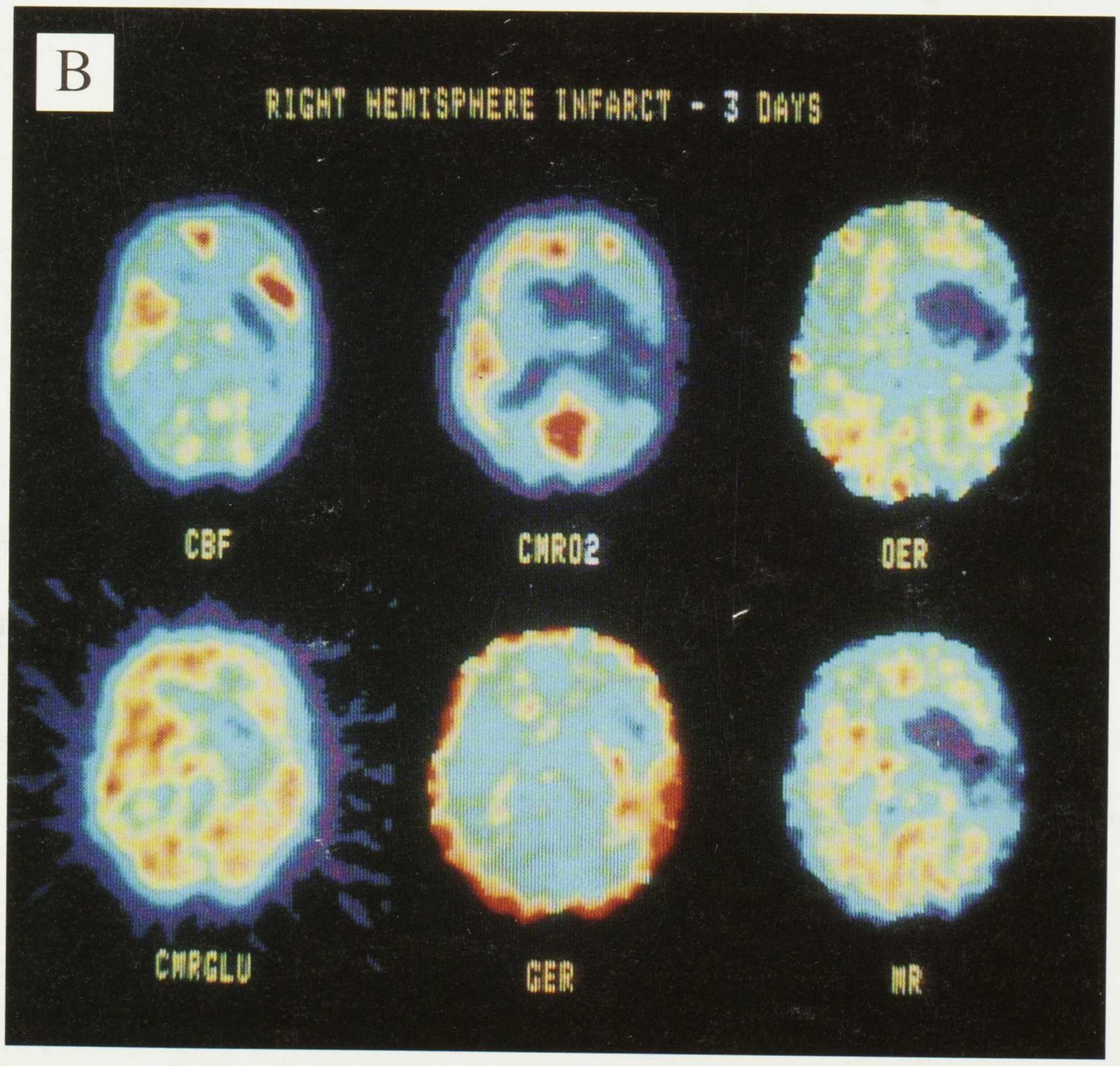

POSITRON EMISSION TOMOGRAPHY

These tomographic scans show a normal human brain (A) and one after a stroke (B). Unlike induced lesions in animals, these sophisticated clinical studies are directly relevant to people.

Tomographic Images: Medical Research Council Cyclotron Unit (UK)

1989